

Combined Dynamic ^{18}F -FDG PET Imaging and DCE MRI Prediction of Treatment Response in an Orthotopic Model of Glioblastoma Multiforme

John L. Chunta, Chris Bull, Jeni Baranski, Tracey Woolliscroft, Deanne Lister, Erin Trachet, Patrick McConville and Dick Leopold
Covance Laboratories Inc., 800 Technology Drive, Ann Arbor, MI

Background

Glioblastomas (GBM) are highly aggressive tumors. When patients are treated with the standard of care of combined radiation therapy and temozolomide (TMZ), median survival is less than 15 months. An earlier prediction of treatment response could allow alternative salvage therapies to be applied sooner if efficacy is not evident. Non-invasive medical imaging provides the opportunity to link imaging-based biomarkers to treatment response. It was hypothesized that a multimodality MRI/PET imaging protocol could allow more accurate prediction of treatment response than conventional means.

Methods

Model: 6-7 week old female Hsd:AthymicNude-Fox1nu mice were implanted with 1×10^6 U87MG-luc cells in 10 μl intracranially under isoflurane anesthesia using a stereotactic surgical apparatus.

Treatment: Treatment began on day 42 post-implant (baseline, Day 0) with either vehicle control or TMZ (33.3 mg/kg) delivered orally once a day for 5 days and PET/MRI imaging was acquired at baseline and +5 days and +15 days post treatment.

Staging: Animals were staged for treatment using a T2-weighted MRI sequence and treatment groups were populated to have as consistent a mean tumor volume as possible (10-20 mm^3).

DCE MRI: A dynamic multi-slice gradient echo sequence was used to image the entire volume of the tumor over time. Nine contiguous transaxial slices were imaged, with the slice thickness scaled to ensure complete coverage of the tumor (0.5-1 mm). 60 x 10 second consecutive images were acquired over a total of 10 minutes. The first minute comprised of pre-contrast injection scans. At 1 minute following the commencement of imaging, the contrast was injected as a bolus (4 times the mg/kg clinical dose equivalent) over 20 seconds, with the exact volume scaled by the body weight of the mouse, which effectively adjusted the total gadolinium dose. The rate of injection was accordingly scaled with body weight to ensure a uniform injection time of 20s. The dynamic contrast enhanced time course was then acquired over the remainder of the 10 minutes of imaging. MRI parameters used were: repetition time (TR)=80 ms; echo time (TE)=2 ms; flip angle = 90 $^\circ$; SW= 40 kHz; square field of view = 20 mm; Image matrix = 64 x 64.

FDG PET Imaging: Dynamic PET acquisitions were initiated just prior to the injection of 200 μCi ^{18}F -FDG and list mode data was then acquired continuously from 0-70 minutes.

Data Analysis: Ktrans was determined by fitting the Gd time course data to a generalized 2-compartment kinetic model (Tofts-Kermode approach) and calculated on a voxel-by-voxel basis. PET was reconstructed with a 2D OSEM algorithm and data was analyzed with traditional kinetic analysis to derive the transfer constant (Ki) using compartmental modeling from 12-70 min and for the SUV_{mean} and SUV_{max} . Correlations were made between relevant parameters to discern the presence of complimentary relationships across the imaging modalities used in this study.

Results and Discussion

Control animals had a median lifespan of 59 days. Animals treated with TMZ had a significant increase in median lifespan of 87 days, as compared to controls ($p=0.002$) and this difference was also reflected in comparisons on tumor size ($P<0.0001$). Comparisons of the influx constant, Ki, derived from dynamic PET data showed no significant differences between control and treated groups, regardless of whether mean or maximum values were used. Similarly, there were no significant differences between groups in the SUV_{mean} and SUV_{max} . Comparisons in the Ktrans between treatment groups resulted in a significant difference at +15 days post-treatment ($p<0.05$). Finally, correlations between the Ktrans and K1 (from FDG compartmental modeling), both of which are a reflection of transfer from the vascular compartment to the extracellular compartment, did not result in a significant relationship.

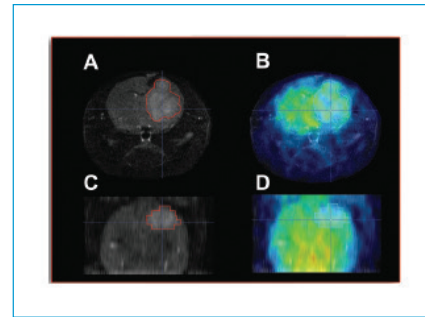


Figure 1. Representative images of T2-weighted MRI of U87-luc orthotopic tumor bearing animal (A, C) and a fused FDG PET/MRI (B, D).

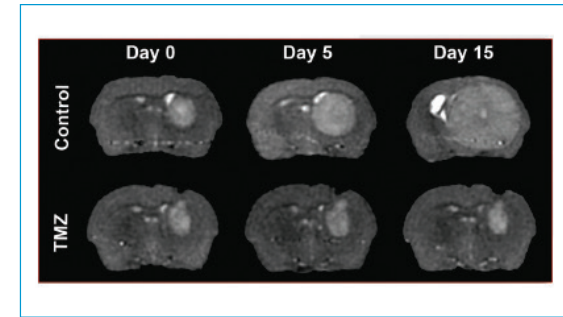


Figure 2. Representative images of T2-weighted MRI of U87-luc tumors in vehicle control animals (top) and temozolomide-treated animals (bottom) at baseline, +5 days and +15 days post-treatment.

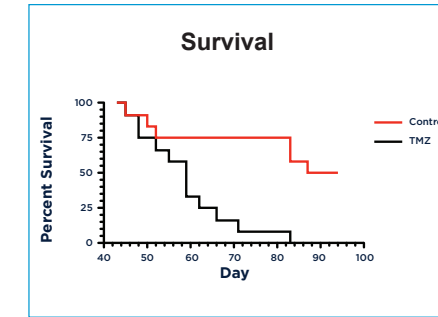


Figure 3. Survival curves of vehicle control animals (black line) and temozolomide-treated animals (red line). Treatment began on day 42 post-implant (baseline day 0) and continued for 5 continuous days with combined dynamic FDG PET and DCE MRI acquired at baseline and days 47 and 57 (+5 and +15 days post-treatment). Treatment with temozolomide produced a significant ($p<0.002$) difference in the life span as compared to vehicle controls.

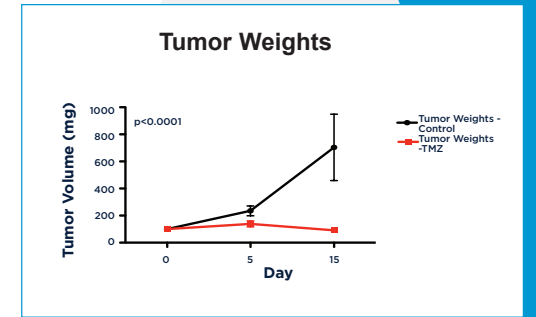


Figure 4. T2 MRI-derived tumor weights acquired at baseline and days 47 and 57 (+5 and +15 days post-treatment). Treatment with temozolomide produced a significant ($p<0.0001$) difference in the tumor weights as compared to vehicle controls.

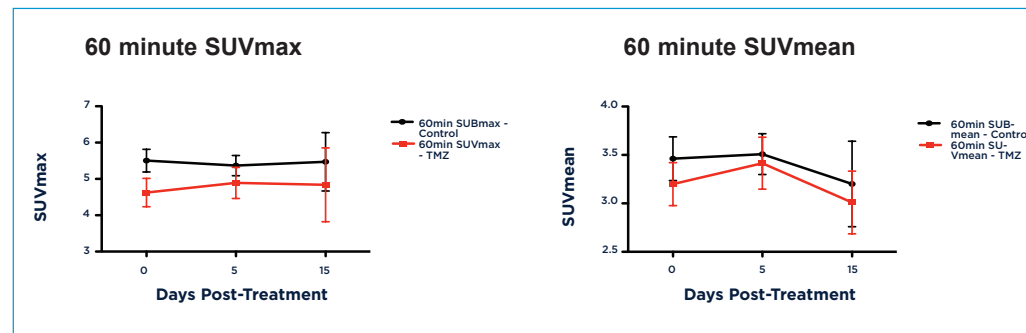


Figure 5. Graphs of FDG PET SUV_{max} (left) and SUV_{mean} (right) acquired at baseline and days 47 and 57 (+5 and +15 days post-treatment). Treatment with temozolomide did not result in a different metabolic response as compared to vehicle controls. Compartmental modeling to derive the influx constant Ki also did not result in a significant difference between the two groups (data not shown).

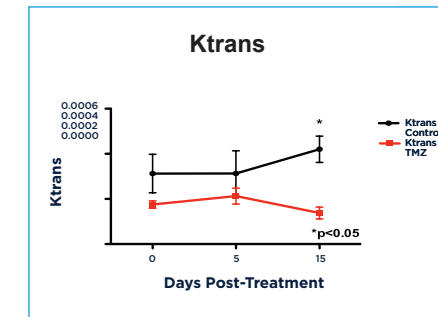


Figure 6. Graphs of DCE MRI derived Ktrans acquired at baseline and days 47 and 57 (+5 and +15 days post-treatment). Treatment with temozolomide resulted in a decrease in Ktrans as compared to vehicle controls.

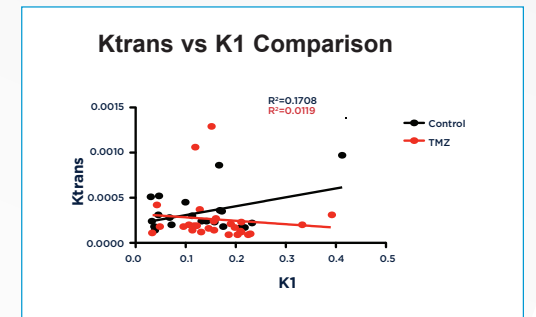


Figure 7. Comparison of the DCE MRI derived Ktrans and the dynamic FDG PET derived K1 from all time points. K1 is a component of the influx constant (Ki) calculation that represents the transfer of FDG from the blood compartment to the extracellular compartment. There was no significant correlation between these two parameters, nor was there a correlation between the Ktrans and the Ki (data not shown).

Conclusions

Both control and TMZ-treated animals produced expected median lifespan results that were significantly different, as compared to historical data. This observation was confirmed in the analysis of tumor weights derived from anatomical T2 MRI images. Static and dynamic analysis of ^{18}F -FDG PET data did not demonstrate differences between treated and untreated groups. It is possible that the time interval to differentiate the two groups was too proximate to extrapolate response from the derived parameters or that ^{18}F -FDG is not the optimal tracer for this type of analysis. Analysis of the Ktrans did produce a statistically significant difference in the TMZ-treated animals as compared to controls.

Comparisons that sought to correlate the Ktrans with the various metabolic analyses did not result in any significant relationships. Of particular note, it was expected that the Ktrans and K1 from FDG compartmental modeling would correlate in some regard since they both measure the transfer of each tracer (FDG and Gd) from the vascular compartment to the extracellular compartment. Unfortunately, no relationship was observed between these two parameters. This could be the result of the different transport/diffusion properties of Gd versus FDG.

Based on the results of this study, it is proposed that future studies utilize later time points in evaluating ^{18}F -FDG-derived biomarkers and/or evaluate the utility of alternate radiotracers (e.g. ^{18}F -FLT for proliferation). Analysis of Ktrans derived from DCE MRI data revealed a significant difference at +15 days post treatment, suggesting that the biomarker selected for a given study is exquisitely sensitive to the time frame intervals between comparator time points. Additionally, it is expected that combining radiation therapy with TMZ will produce more measurable differences in these biomarkers at early time points. A hybrid metric that combines PET and DCE MRI outputs is under development as an enhanced predictor of response with results forthcoming.